

RING CHROMOSOME 13 SYNDROME IN AN ADULT MALE WITH MILD MENTAL RETARDATION

Takeshi Matsuishi¹⁾

Anne Millar²⁾

Tetsuaki Yamaguchi³⁾

Keiko Endo³⁾

¹⁾Yokohama National University, Faculty of Education, Department of Special Education

²⁾Yokohama Rehabilitation Centre, Department of Rehabilitation

³⁾Yokohama City University, School of Medicine, Department of Psychiatry

ABSTRACT

A case of ring 13 syndrome in an 18-year-old male is presented with particular focus on mental retardation. The clinical picture was characterized by mild mental retardation, microcephaly, large low set ears, a broad nasal bridge, epicanthus, micrognathia and short philtrum. A review of the literature with a focus on mental retardation concluded that descriptions of mental retardation were often unqualified and at times ambiguous. Furthermore, in contrast to the characteristic description of ring chromosome 13 syndrome which describes marked mental retardation a small number of cases with mild mental retardation exist.

Keyword chromosomal abnormality, mental retardation, ring chromosome 13 syndrome.

INTRODUCTION

Ring chromosomes show much diversity in their resulting clinical features. It is said that ring 13 exhibits the least clinical variation (Martin et al. 1982) and a defined syndrome has been gradually emerging since it was first described by Lejeune et al. in 1968. The present clinical picture is one characterised by marked mental retardation, microcephaly, craniofacial dysmorphism and physical malformations. In this paper we describe a new case of ring chromosome 13 syndrome in an 18-year-old man. As the literature is dominated by detailed accounts of the physical presentation of these cases we focus on mental retardation and present a review of the literature from this viewpoint.

Name and Address for the correspondence

Name: Dr. Takeshi Matsuishi Yokohama National University, Department of Special Education

Address: 79-2, Tokiwadai, Hodogayaku, Yokohama City, 240, Japan

CASE REPORT

The patient was born at 40 weeks after an uneventful pregnancy to a 21-year-old mother and a nonconsanguineous 28-year-old father. Both parents are healthy. The delivery was complicated by looping of the umbilical cord around the proband's neck causing slight asphyxia. Birth weight was 2640 g, length was 47 cm and head circumference was 30 cm. The patient is the eldest of 3 siblings all of whom are physically and mentally normal.

Past medical history reveals mental and physical developmental delay. Acquisition of motor milestones was retarded. First steps were taken at one year and 6 months and first words at two years 6 months. At age 10, in 4th grade of elementary school, he was transferred from a mainstream class to a special class for mild mental retardation within the same school. After graduating junior high school he was then placed in a special school from which he graduated at age 18. At that time he was referred for psychological evaluation where he scored 58 on the Tanaka-Binet IQ test, thus classifying him as mildly mentally retarded. From there he was placed in a job in a bakery.

On examination at age 18 the patient presented with microcephaly and facial dysmorphism including large low set ears, a broad nasal bridge, epicanthus, micrognathia and a short philtrum (fig.1). Height was 165 cm, weight 43 kg and head circumference 52 cm. Neurological examination was unremarkable.

Fig.1 Facial view of the patient

Chromosomal analysis performed on 30 peripheral blood lymphocytes by the G-Banding technique revealed ring chromosome 13 in all 30 cells. By high-resolution G-Banding the breakpoints were identified (Fig.2). We can describe the karyotype thus: 46, XY, r(13)(p11q34).

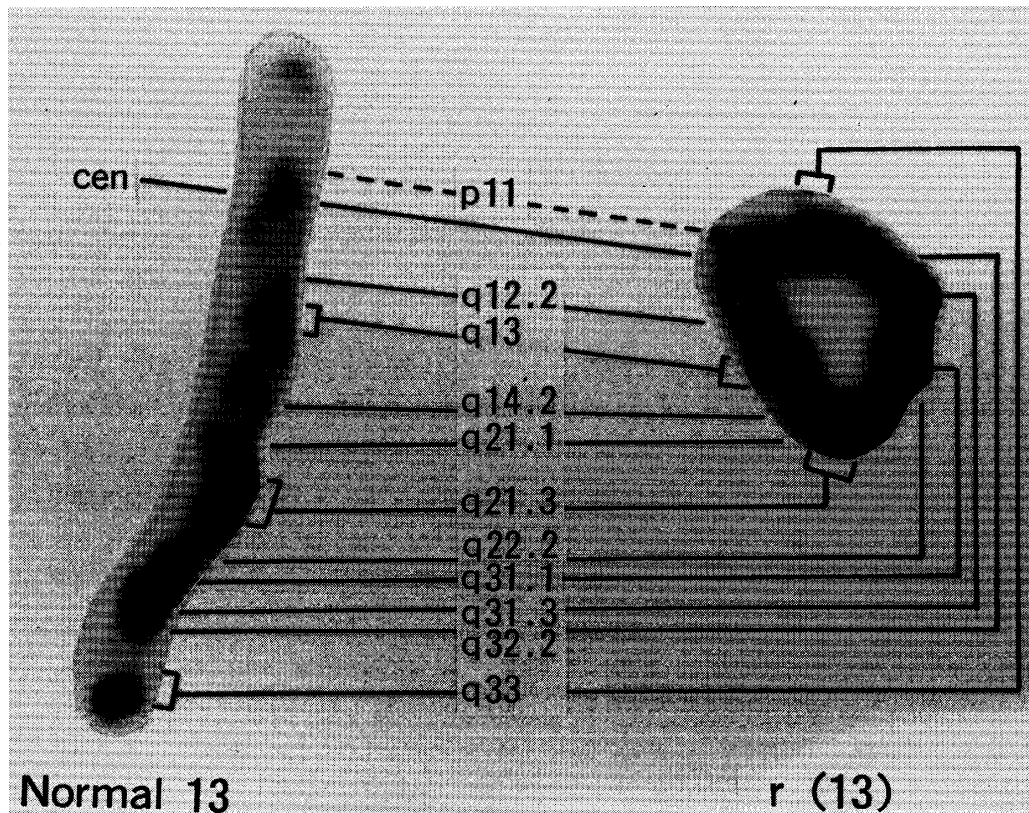


Fig.2 High-resolution G-banding shows ring chromosome 13: karyotype is 46, XY, r (13) (p11q34)

The patient presented as a very sociable and cheerful young man. His verbal intelligence was high and he possessed good language skills. He could describe his hobbies and interests fluently. He is independent in all activities of daily living and in the use of public transport. Both in his home life and working life he has many responsibilities. At home he takes care of the dog and does shopping errands. At the bakery he is responsible for collecting and distributing bread to designated areas.

Discussion

A number of investigators have indicated that ring chromosome 13 syndrome exists as a clinical entity or entities (Niebuhr & Ottosen 1973 ; Martin et al. 1982 ; Parcheta et al. 1985). Niebuhr & Ottosen (1973) suggested three possible distinct clinical syndromes involving chromosome ring 13 based on the variable loss of genetic material from the long arm of chromosome 13 during ring formation : group I, with loss of segments 13q34 and possibly 13q33, is associated with severe mental retardation, microcephaly with true hypertelorism, salient frontal bossing erasing the nasal bridge, forward-slanting maxillary incisors, and large ears with deep sulci ; group II, with a loss of the segment 13q32 and part of 13q31, is

associated with the clinical features of group I plus aplasia or hypoplasia of the thumbs, foot or toe abnormalities, severe genital malformations, anal atresia, and eye malformation; group III, with a breakpoint at 13q21 is characterized by retinoblastoma. Based on this classification our case would appear to belong to group I. While some clinical features specific to this group were observed, such as microcephaly and large ears, the extent of facial dysmorphism and mental retardation were significantly slighter. The existence of such a distinct pattern based on breakpoints is thought to be unlikely by some authors (Steinbach et al. 1981; Hoo et al. 1974; Brandt et al. 1992)

Following a review of the previously reported 21 cases with identified breakpoints it appears that the main focus is on physical presentation and the existence or not of a clinical syndrome based on breakpoints. While severe mental retardation is cited as a characteristic feature of ring chromosome 13 syndrome (Rethoré & Pinet 1987) little quantitative or qualitative descriptions regarding mental development could be found. It is this aspect of ring chromosome 13 syndrome that we wish to focus our attention on in this paper. In a review of the above mentioned 21 cases 2 were still born (Stetten et al. 1990; Brandt et al. 1992), one of which was anencephalic (Brandt et al. 1992), 10 were described as severely mentally retarded (Mikkelsen & Niebuhr 1969; Fryns et al. 1974; Magenis et al. 1976; Cossu et al. 1979; Lagergren et al. 1980; Jones et al. 1981; Steinbach et al. 1981; Martin et al. 1982), 6 were described non-specifically as mentally retarded (Niebuhr & Ottosen 1973; Hoo et al. 1974; Noel et al. 1976; Steinbach et al. 1981; Martin et al. 1982; Parcheta et al. 1985) and 3 were described as mild to moderately mentally retarded (Verma et al. 1978; Hernandez et al. 1979; McCorquodale et al. 1989). A correlation between the degree of mental retardation and breakpoint could not be identified. However all mild and moderate cases including this case have a breakpoint at q34.

With regard to the present case we conclude our patient to be mildly mentally retarded. Hernandez et al. (1979) describe a girl of 9 years with mildly delayed psychomotor retardation and an IQ of 60. The case described by McCorquodale et al. (1986) of a 5 year old boy is moderately mentally retarded. Finally the case of a 2 years and 8 month old girl presented by Verma et al. (1978) appears to be mildly mentally retarded.

While it is evident that the majority of the reported cases fall into the severely mentally retarded category it is not the 100% as described by Brandt et al. (1992) who reviewed almost the same cases. Indeed contrary to the classic profile of ring chromosome 13 syndrome (Rethoré & Pinet 1987), we would like to emphasize mild and moderate levels of mental retardation exist in ring chromosome 13 syndrome patients.

Up to now little attention has been paid to the mental and psychomotor development in patients with ring syndrome 13 syndrome. Further detailed and accurate descriptions of mental development are urgently needed in order to extend the knowledge on their long term mental prognosis.

References

- Brandt C.A., Hertz J.M., Petersen M.B., Vogel, F., Noer H. & Mikkelsen M. (1992) Ring chromosome 13: lack of distinct syndromes based on different breakpoints on 13q. *Journal of Medical Genetics* 29, 704-8.
- Cossu P., Diana G., Mameli M., Cardia S., Millia A., Floris G. & Cao A. (1979) A case of D₁₃ ring chromosome. *Human Genetics* 46, 111-4.
- Fryns J.P., Deroover J. & Van den Berghe H. (1974) Malformative syndrome with ring chromosome 13. *Humangenetik* 24, 235-40.
- Hernandez A., Garcia-Cruz D., Plascencia L., Nazara Z., Rivera H., Sanchez-Corona J. & Cantu J.M. (1979) Some clinical and cytogenetic observations on a ring chromosome 13(p11q34). *Annales de Génétique* 22, 221-4.
- Hoo J.J., Obermann U. & Cramer H. (1974) The behavior of ring chromosome 13. *Humangenetik* 24, 161-71.
- Jones I.M., Palmer C.G., Weaver D.D. & Hodes M.E. (1981) Study of two case of ring 13 chromosome using high-resolution banding. *American Journal of human Genetics* 33, 252-61.
- Lagergren M., Börjeson M. & Mitelman F. (1980) Prophase analysis of ring chromosome 13- an attempt at phenotype-karyotype correlation. *Hereditas* 93, 231-3.
- Lejeune J., Lafourcade J., Berger R., Cruveiller J., Rethoré M.O., Dutrillaux B., Abonyi D. & Jérôme H. (1968). Le phenotype (Dr). Etude de trois cas de chromosomes D en anneau. *Annales de Génétique* 11, 79-87.
- Magenis R.E., Wyandt H.E., Overton K.M. & Macfarlane J. (1976) Parental Origin of a ring 13 chromosome in a female with multiple anomalies. *Human Genetics* 33, 181-6.
- Martin N.J., Harvey P.J. & Pearn J.H. (1982) The ring chromosome 13 syndrome. *Human Genetics* 61, 18-23.
- McCorquodale M.M., Kolacki P., Kurczynski T.W. & Baugh E. (1986) Tissue-specific mosaicism for the stability of a ring 13 chromosome. *Journal of Mental Deficiency Research* 30, 389-99.
- Mikkelsen M. & Niebuhr E. (1969) A ring chromosome (46, XY, 13r) occurring in a family with a D-D translocation 13-14,t (13q 14q). *Annales de Génétique* 12, 51-6.
- Niebuhr E. & Ottosen J. (1973) Ring chromosome D (13) associated with multiple congenital malformations. *Annales de Génétique* 16, 157-66.
- Noel B., Quack B. & Rethré M.O. (1976) Partial deletions and trisomies of chromosome 13; mapping of bands associated with particular malformations. *Clinical Genetics* 9, 593-602.
- Parcheta B., Wisniewski L., Piontek E., Szymanska J., Skawinski W. & Wrmenski K. (1985) Clinical features in a case with ring chromosome 13. *European Journal of Pediatrics* 144, 409-12.
- Rethoré M.O. & Pinet J. (1987) New deletion and ring chromosome syndromes. In: *Malformation* (eds P.J. Vinken, G.W. Bruyn & H.L. Klawans), 577-97. ELSEVIER SCIENCE

PUBLISHERS, Amsterdam.

Steinbach P., Drews K., Horstmann W., Barbi G. & Scholz W. (1981) Two case of ring chromosome 13. Chromosome banding patterns and mosaic configuration. *Annales de Génétique* 24, 152-7.

Stetten G., Tuck-Muller C.M., Blakemore K.J., Wong C., Kazazian Jr H.H. & Antonarakis S.E. (1990) Evidence for involvement of a Robertsonian translocation 13 chromosome in formation of a ring chromosome 13. *Molecular Biology & Medicine* 7, 479-84.

Verma R.S., Dosik H., Chowdhry I.H. & Jhaveri R.C. (1978) Ring chromosome 13 in a child with minor dysmorphic features. *American Journal of Disease of Children* 132, 1018-21.